

RESEARCH

Open Access



Carbon dioxide dialysis in a swine model utilizing systemic and regional anticoagulation

A. S. Sharma^{1*}, P. W. Weerwind¹, O. Bekers², E. M. Wouters³ and J. G. Maessen¹

* Correspondence:

ajay.sharma@maastrichtuniversity.nl

¹Department of Cardiothoracic Surgery, CARIM, Maastricht University Medical Center, PO box 5800, 6202 AZ Maastricht, the Netherlands
Full list of author information is available at the end of the article

Abstract

Background: Extracorporeal carbon dioxide removal (ECCO₂R) has been gaining interest to potentially facilitate gas transfer and equilibrate mild to moderate hypercapnic acidosis, when standard therapy with non-invasive ventilation is deemed refractory. However, concern regarding the effectiveness of low-flow CO₂ removal remains. Additionally, the prospect to steadily reduce hypercapnia via low-flow ECCO₂R technique is limited, especially with regional anticoagulation which potentially reduces the risk of bleeding. Therefore, an in vivo study was conducted to determine the efficacy of CO₂ removal through a modified renal dialysis unit during the carbon dioxide dialysis study using systemic and regional anticoagulation.

Methods: The acute study was conducted for 14 h in landrace pigs (51 ± 3 kg). CO₂ removal using a diffusion membrane oxygenator substituting the hemoconcentrator was provided for 6 h. Blood and gas (100 % O₂) flows were set at 200 and 5 L/min, respectively. Anticoagulation was achieved by systemic heparinization ($n = 7$) or regional trisodium citrate 4 % ($n = 7$).

Results: The CO₂ transfer was highest during the initial hour and ranged from 45 to 35 mL/min, achieving near eucapnic values. Regional and systemic anticoagulation were both effective in decreasing arterial pCO₂ (from 8.9 ± 1.3 kPa to 5.6 ± 0.8 kPa and from 8.6 ± 1.0 kPa to 6.3 ± 0.7 kPa, $p < 0.05$ for both groups, respectively). Furthermore, pH improved (from 7.32 ± 0.08 to 7.47 ± 0.07 and from 7.37 ± 0.04 to 7.49 ± 0.01, $p < 0.05$) for both regional and systemic anticoagulation groups, respectively. Upon ceasing CO₂ dialysis, hypercapnia ensued. The liver and kidney function test results were normal, and scanning electron microscopy analysis revealed only some cellular and fibrin adhesion on the oxygenator fibre in the heparin group.

Conclusions: CO₂ dialysis utilizing either regional or systemic anticoagulation showed to be safe and effective in steady transfer of CO₂ and consequently optimizing pH.

Keywords: Acute-on-chronic hypercapnic respiratory failure, Low-flow CO₂ removal, Regional anticoagulation, Systemic anticoagulation, Animal model

Background

Chronic obstructive pulmonary disease (COPD) patients presenting with mild to moderate hypercapnic respiratory acidosis are often supported by non-invasive ventilation (NIV) to facilitate gas transfer and prevent progression into severe acidosis [1]. In about 25 to 50 % of these patients, NIV may not be effective in improving the respiratory mechanics with a consequent need for invasive ventilation [2]. Hence, alternative approaches to facilitate gas transfer have been sought, including the application of extracorporeal carbon dioxide removal (ECCO₂R) technique [3]. ECCO₂R technique primarily supports decarboxylation and thereby improves respiratory acidosis, finding its application relevant in reversible type 2 respiratory failure situations.

CO₂ is primarily transported in a dissolved state in plasma and can be extracted effectively through a membrane lung when connected to high sweep gas flows [4, 5]. Other determinants that influence gas transfer are membrane surface area, partial pressure of CO₂ (pCO₂) concentration before the membrane lung, and even the type of membrane [5–7]. Terragni et al. describe that ECCO₂R application at sweep gas flows of 6 to 8 L/min and blood flows of approximately 500 mL/min has shown to extract approximately 80 mL of CO₂/min, which accounts for 40 % of the calculated CO₂ production [3]. While Burki et al. in a pilot study reported that with ECCO₂R application at low blood flow (approximately 500 mL/min), a subset of patients with underlying COPD could be managed without invasive mechanical ventilation [8]. Although, these described techniques require the use of specially designed cannula or even devices [9–11] that could increase the healthcare costs. Since COPD is a growing concern world-wide, adapting a pre-existing renal dialysis unit and providing CO₂ removal at even lower blood flows through the modified system could potentially support patients over an extended period of time to avert rapid correction of the acid-base balance in mild to moderate acidosis, when NIV is contradicted or proves to be insufficient.

Furthermore, to prevent clotting of the extracorporeal circuit, heparin is administered as a systemic anticoagulant [8]. However, heparin induces bleeding and has been reported up to 40 % of patients placed on veno-venous extracorporeal support [12, 13]. Thus, this concern also extends to the application of ECCO₂R technique. Alternatively, regional anticoagulation likely circumvents heparin-induced bleeding and seems to be an attractive option [14]. Regional anticoagulation with trisodium citrate has been extensively used to maintain circuit patency with safer and simple protocols in renal replacement therapy [15, 16]. Moreover, exogenously administered citrate metabolizes to sodium bicarbonate [17], which might be beneficial in acute respiratory acidosis. However, this chemical buffering effect in low-flow ECCO₂R systems has not been verified.

We hypothesize that implementing dialysis flows and opting for regional anticoagulation with trisodium citrate might benefit patients with hypercapnic respiratory failure. Therefore, in a swine model, the efficacy of CO₂ removal at a dialysis flow rate using regional trisodium citrate anticoagulant and also systemic anticoagulant was determined utilizing a modified renal dialysis unit.

Methods

This in vivo study was conducted at the Department of Cardiothoracic Surgery, Experimental Laboratory, Maastricht University, the Netherlands. The study was approved by the local animal investigation committee of the Maastricht University. Animal handling

was in accordance with the guide and use of laboratory animals (published by the National Institute of Health, USA).

Overview of study

Fourteen healthy domestic landrace pigs weighing 51 ± 3 kg were studied. The animals were divided into two groups based on either systemic anticoagulation with heparin (group 1, $n = 7$) or regional anticoagulation using 4 % trisodium citrate (group 2, $n = 7$).

Each experiment was conducted over a duration of 14 h, divided into four subsequent phases: stabilization phase (0–60 min), hypercapnic phase (60–360 min), intervention phase (360–720 min), and post-intervention phase (720–840 min).

Animal preparation

The animals were sedated with a mixture of intramuscular administered ketamine (10 mg/kg), midazolam (0.5 mg/kg), and atropine (0.04 mg/kg). Induction of anaesthesia and analgesia was achieved by an intravenous injection of thiopental sodium (5 mg/kg), midazolam (0.5 mg/kg), and sufentanyl citrate (6 μ g/kg). Following endotracheal intubation, mechanical ventilation (Datex Engstrom, Instrumentarium Corporation, Helsinki, Finland) was ensued and animals were stabilized on a volume-controlled setting with a respiratory rate (RR) of 10–12 breaths/min, a tidal volume (V_t) of 10 mL/kg/min, a positive end expiratory pressure (PEEP) of 3 cm of H_2O , a fraction of inspired oxygen (FiO_2) of 0.5, and an inspiratory to expiratory (I:E) ratio of 1:2.

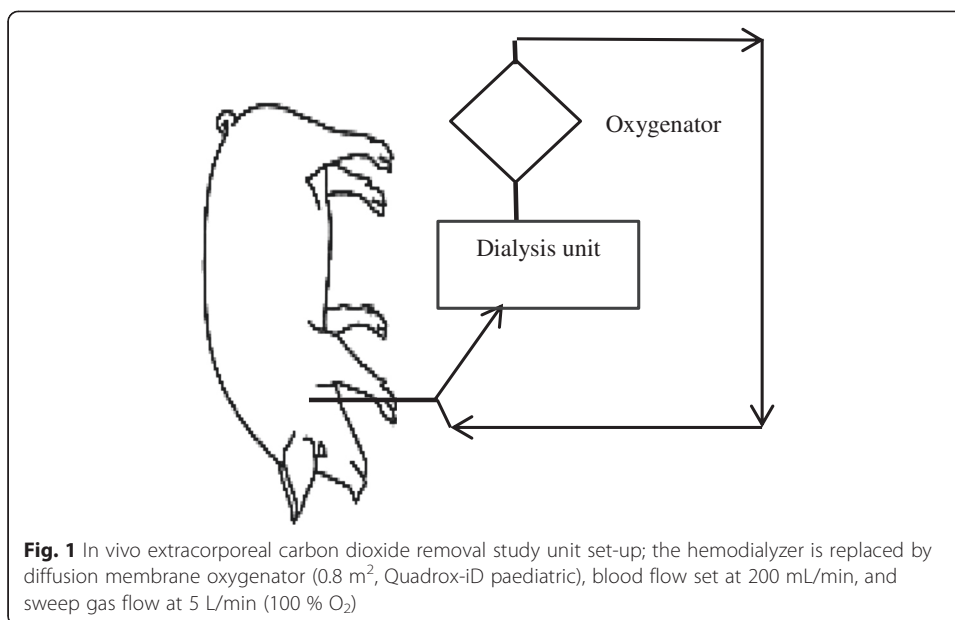
Anaesthesia, analgesia, and muscle relaxation were maintained with intravenous administration of midazolam (1.0 mg/kg/h) additionally supported by Isoflurane (0.5–1 %), sufentanyl citrate (4 μ g/kg/h), and pancronium bromide (0.1 mg/kg/h). Limb lead electrocardiogram (ECG) and oxygen saturation (ML320/E Oximeter POD, PowerLab, AD Instruments, Oxfordshire, UK) were recorded and monitored continuously. Body temperature was maintained within normal range (37.5–38.0 °C). Intravenous infusion of Ringer's lactate was provided. The femoral vessels (artery and vein) and pulmonary artery were catheterized to measure the mean arterial pressure, central venous pressure, and cardiac output.

Hypercapnic phase

The hypercapnic phase was induced by resetting the ventilator to a lower V_t of 6 ml/kg/min, while maintaining other baseline parameters (RR 10–12 breaths/min, PEEP 3 cm H_2O , FiO_2 0.5, and an I:E ratio of 1:2). The reduced V_t of 40 % was maintained for the remainder period of the experiment.

CO₂ dialysis unit set-up and cannulation procedure

The CO₂ dialysis unit consisted of a continuous veno-venous hemofiltration device (Baxter BM11, Baxter Healthcare Corporation, Deerfield, IL, USA), a Bio-line coated diffusion membrane oxygenator (0.8 m², Quadrox-iD paediatric, Maquet Cardiopulmonary, Rastatt, Germany) that replaced the hemoconcentrator (as shown in Fig. 1) and was primed with 200 mL of 4 % Gelofusine (B. Braun AG, Melsungen, Germany). At end of the hypercapnic phase, the animals in group 1 received an intravenous bolus injection of heparin (20 IU/kg) and the right internal jugular vein was catheterized using a regular single



double lumen dialysis catheter (14 Fr. × 10", 25 cm; Arrow international, Reading, PA, USA). A continuous infusion of heparin at the inflow port of the dialysis catheter maintained the activated partial thromboplastin time (aPTT) between 60 and 80 s, measured hourly. In group 2, the regional anticoagulation was started as soon as the catheter was placed through the inflow port of the dialysis catheter. In both groups, 100 mL of priming volume was discarded immediately after the circuit was connected to the dialysis catheter. The correct placement of the dialysis catheter was confirmed by fluoroscopy.

Intervention phase

The sweep gas flows (100 % O₂) through the diffusion membrane were titrated to 5 L of oxygen, and the blood flow was maintained at 200 mL/min. In group 2, Ringer's lactate infusion was tapered accordingly, since there was continuous infusion of 4 % trisodium citrate at the inflow port of the catheter, which chelated the ionized calcium of inflowing blood. A continuous infusion of calcium gluconate 10 % at the outflow port of the catheter maintained the systemic ionized calcium. Monitoring of anticoagulation in this group was performed by hourly measurement of the ionized-calcium levels at the post-oxygenator and in the animal. The infusions of 4 % trisodium citrate and calcium gluconate were titrated accordingly to maintain the ionized-calcium level between 0.25 and 0.35 mmol/L [15] in the dialysis circuit and a systemic ionized-calcium level of 1.12–1.20 mmol/L.

Post-intervention phase

The CO₂ dialysis was terminated, and the dialysis circuit was disconnected after clamping the inflow and outflow ports. The animals continued to be on mechanical ventilation, while the disposable parts of the circuits were separated, flushed with saline, and visually inspected for clot formation. Parts of the diffusion membrane were collected for scanning electron microscopy (SEM) analysis, and following post-intervention

phase, the animals were euthanized under general anaesthesia using a single dose of pentobarbital (150 mg/kg).

Measurements

Hourly samples for blood gases were drawn and analysed (Gem Premier 3000, Instrumentation Laboratory, Lexington, MA, USA). Blood samples for liver function and renal function tests were collected to monitor the acute metabolic effects of citrate. The aPTT was measured using a Hemochron Jr. Signature (Edison, USA). Cardiac output was measured by thermo-dilution.

CO₂ transfer rate was calculated using the following formula:

$$\text{CO}_2 \text{ transfer rate} = Q_{\text{gas}} * \text{Percentage of CO}_2 * 10$$

where Q_{gas} is the gas flow through the oxygenator and percentage of CO₂ is the CO₂ at the gas outlet port of the oxygenator, measured by capnograph (Novamatrix Capnogard, Philips Respironics, Best, The Netherlands).

Statistical analysis

Statistical analysis was performed with SPSS 21.0 software (SPSS, Chicago, IL, USA). Continuous data are presented as mean \pm standard deviation or median with interquartile range as appropriate. The continuous variables were subjected to normality distribution. Accordingly, continuous variables of paired samples within the group were analysed by the Wilcoxon signed-rank test, and differences between two continuous variables were analysed by the Mann-Whitney U test. A p value <0.05 was considered statistically significant.

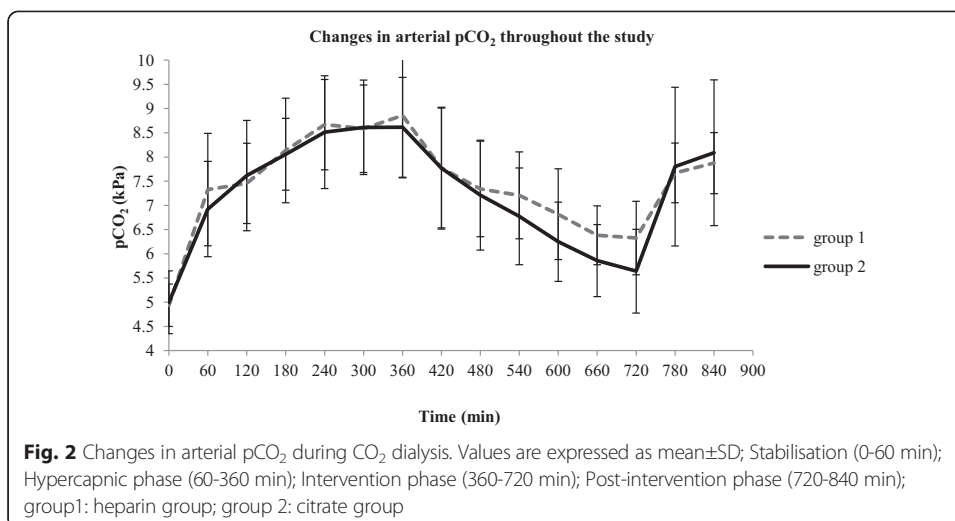
Results

CO₂ dialysis (200 mL/min) with systemic anticoagulation (group 1) and regional anticoagulation (group 2) was applied in an in vivo study. The physiological parameters (e.g. mean blood pressure, heart rate, and cardiac output) remained within normal physiological limits.

CO₂ transfer across the oxygenator was maximal at 45 mL/min and stabilized during the course of the intervention at 35 mL/min in both groups ($p > 0.05$). Furthermore, the mean pCO₂ values/unit time during intervention were not significantly different between the groups that received systemic anticoagulation vs. regional anticoagulation ($p > 0.05$). A steady CO₂ removal was observed in both groups, as depicted by the mean changes in arterial pCO₂ (Fig. 2).

Consequently, pH improved from 7.32 ± 0.08 to 7.47 ± 0.07 in group 1 and from 7.37 ± 0.04 to 7.49 ± 0.01 in group 2, $p < 0.05$ for both groups (Table 1). Further, in group 1, a significant change in pCO₂ was observed at the first hour of intervention and at different time points during the experimental phase. In contrast, in group 2, equilibration of CO₂ reflected by changes in pCO₂ occurred throughout the intervention phase (Table 2).

The arterial pO₂ during intervention remained at a mean of 13.2 ± 0.3 kPa in group 1 while it was a mean of 14.1 ± 0.7 kPa in group 2. Transoxygenator pressure difference varied between 10 and 15 mmHg. The liver function tests (alkaline phosphatase 88.0 ± 11.0 IU/L; gamma glutaryl transferase 14 ± 2.0 IU/L; aspartate aminotransferase 22.0 ± 5.0 IU/L; alanine aminotransferase 44.0 ± 2.0 IU/L; total bilirubin 2.2 ± 0.2 $\mu\text{mol/L}$;



direct bilirubin $2.2 \pm 0.2 \mu\text{mol/L}$) and renal function test (creatinine $103.0 \pm 0.7 \mu\text{mol/L}$) were within normal range. SEM analysis (Fig. 3a) of the diffusion membrane revealed only some cellular and fibrin adhesion on the oxygenator fibre in the heparin group (Fig. 3b).

Discussion

Low-flow CO₂ removal was efficient in establishing eucapnia in a swine model. A mean CO₂ extraction of 40 mL/min through a modified renal dialysis unit permitted adequate gas transfer under constant low volume ventilatory support. Consequently, arterial pH improved within the initial hour of intervention, highlighting the efficacy of the gas-exchange diffusion membrane even at a low blood flow rate.

Hypercapnic respiratory failure worsens prognosis and increases mortality in COPD patients [18, 19]. The pathophysiological alterations precipitating this condition include dynamic hyperinflation and expiratory flow limitation as a result of respiratory muscle fatigue, which further aggravates respiratory acidosis. NIV is therefore considered as a standard mode of treatment to provide ventilation support among these patients, to improve acidemia (pH ≤ 7.35 and/or arterial pCO₂ $\geq 6.0 \text{ kPa}$ [1]. In the majority of patients, NIV application has been found effective to avert imminent respiratory arrest. However, a well-demarcated contradiction to apply NIV is the presence of co-morbidities [20]. Moreover, failure of NIV hinders its application or even the effectiveness of the therapy.

Table 1 Arterial pH levels between consecutive time points during CO₂ dialysis

	Group 1	<i>p</i> value	Group 2	<i>p</i> value
End of the hypercapnic phase	7.37 ± 0.04		7.32 ± 0.08	
<i>t</i> = 60 min	7.43 ± 0.06	0.01	7.37 ± 0.08	0.02
<i>t</i> = 120 min	7.44 ± 0.05	0.03	7.45 ± 0.09	0.06
<i>t</i> = 180 min	7.45 ± 0.05	0.03	7.45 ± 0.10	0.03
<i>t</i> = 240 min	7.48 ± 0.06	0.02	7.51 ± 0.10	0.02
<i>t</i> = 300 min	7.49 ± 0.01	0.01	7.52 ± 0.10	0.02
<i>t</i> = 360 min	7.49 ± 0.01	0.01	7.47 ± 0.07	0.02

pH values are expressed as mean ± SD; group 1: heparin group; group 2: citrate group; *t*: sampling time point; *p* values are expressed for two consecutive sample points within a group during CO₂ dialysis

Table 2 Arterial pCO₂ levels between consecutive time points during CO₂ dialysis

	Group 1	<i>p</i> value	Group 2	<i>p</i> value
End of the hypercapnic phase	8.9 ± 1.3		8.6 ± 1.0	
<i>t</i> = 60 min	7.8 ± 1.2	0.01	7.8 ± 1.3	0.02
<i>t</i> = 120 min	7.3 ± 0.9	0.11	7.2 ± 1.1	0.04
<i>t</i> = 180 min	7.2 ± 0.9	0.13	6.8 ± 1.0	0.02
<i>t</i> = 240 min	6.8 ± 0.9	0.01	6.2 ± 0.8	0.02
<i>t</i> = 300 min	6.4 ± 0.6	0.01	5.9 ± 0.7	0.02
<i>t</i> = 360 min	6.3 ± 0.8	0.91	5.6 ± 0.8	0.03

pCO₂ values are expressed as mean ± SD; group 1: heparin group; group 2: citrate group; *t*: sampling time point; *p* values are expressed for two consecutive sample points within a group during CO₂ dialysis




Fig. 3 a Scanning electron micrograph of an oxygenator fibre in the heparin group showing some cellular and fibrin adhesion. **b** Scanning electron micrograph of an oxygenator fibre in the citrate group

Consequently, an invasive approach to provide ventilation is applied, which is associated with a poor survival rate [21]. Therefore, a minimally invasive form of support through extracorporeal CO₂ removal technology has been increasingly considered as a viable alternative to standard therapies [3].

In the recent years, application of ECCO₂R devices has been gathering interest to support patients in hypercapnic respiratory failure refractory to standard therapy [3, 8]. As application of ECCO₂R has been demonstrated to be effective, using blood flows of about 400–1000 mL/min supports gas transfer and ameliorates moderate to severe hypercapnic acidosis [8, 22], thereby reducing pCO₂ (from 10.5 to 8.7 kPa) and improving pH (from 7.28 ± 0.08 to 7.34 ± 0.07) following 1 h of support at a blood flow rate of approximately 500 mL/min [8]. Recently, Kargiannidis et al. reported a swine study which showed improvement of pCO₂ (from about 14.4 to 7.5 kPa) with acidemia equilibrating from 7.13 ± 0.08 to 7.41 ± 0.07 within 15 min of ECCO₂R support at a blood flow rate of 1000 mL/min [22]. Albeit, one of the largely unrecognized concern prevails among such patients when hypercapnia is optimized too rapidly, resulting in metabolic alkalosis which can increase the duration of recovery and hospital stay [23]. Moreover, in situations of acute-on-chronic hypercapnic respiratory failure, a steady removal of CO₂ might be necessary for an extensive period of time, as CO₂ persists in HCO₃-form in slow compartments [22]. Extensive periods of high-flow ECCO₂R support might prove counter-productive, as we might plausibly alter the acid-base balance dramatically. Therefore, low-flow CO₂ removal would be a more controlled and physiological alteration to establish homeostasis in a chronically altered state. As described in our study, a commonly used renal dialysis unit was adapted by incorporating a diffusion membrane oxygenator replacing the hemodialyzer. CO₂ dialysis in our observation resulted in a lower CO₂ extraction (approximately 40 mL/min) compared to currently available veno-venous pump-driven devices (approximately 80 mL/min) [9, 11]. Although, CO₂ dialysis in this current study seems to have a lower CO₂ extraction rate, the ability to increase blood flows with prevalent dialysis devices provides the possibility to increase higher amount of CO₂ extraction when indicated, while opting for a larger size cannula. In patients with underlying renal insufficiency and acute respiratory distress syndrome, Forster and colleagues described the role of low-flow CO₂ removal, where the introduction of a hollow-fibre oxygenator in a renal replacement unit ameliorated acidosis and improved pCO₂ [24]. Although this auxiliary support facilitated improvements, the risk of anticoagulation failure leading to clot formation or bleeding with systemic anticoagulation remains a challenge.

In general, an extracorporeal device such as CO₂ removal system requires systemic anticoagulation [25], to maintain patency and reduce thromboembolic complications. To date, heparin remains the most commonly used anticoagulant in these devices, potentially increasing the risk of bleeding. Additionally, the use of unfractionated heparin in patients susceptible for bleeding can induce thrombocytopenia and hence propagate the risk of systemic bleeding [12, 26]. It would be, therefore, attractive to implement regional anticoagulation with citrate as practised widely in renal dialysis [15] to reduce the potential risk of bleeding. The practice of regional anticoagulation in CO₂ removal has not been prevalent. Cardenas et al. described the use of regional citrate anticoagulation in a CO₂ removal system, but they were challenged with the maintenance of adequate systemic calcium levels [27]. In our study, we used a standard protocol for regional citrate anticoagulation,

where citrate was infused into the inlet port of the catheter chelating calcium. The chelated calcium inhibited the activation of calcium-dependent coagulation factors in the dialysis circuit, providing optimum anticoagulation. The infusion of calcium gluconate in the outlet port of the catheter reversed the citrate effect.

The use of regional anticoagulation with citrate also has additional benefits, such as improving the circuit survival time [15]. Moreover, the secondary gain in administering trisodium citrate is the formation of sodium bicarbonate, which is an end-product of citrate metabolism occurring in the liver, skeletal muscle, and kidney [17]; this might buffer the excess acid. However, this beneficial chemical buffering of CO₂ was observed less evidently, conceivably in view of the efficient CO₂ dialysis system.

Gross thrombus formation, a potential complication in low-flow conditions, was not observed in either the heparin group or the citrate group. Although SEM analysis from the heparin group revealed only some cellular and fibrin adhesion over the diffusion membrane, similar observations were not prominent from the analysis in the citrate group. This latter observation might be due to the chelation of calcium and subsequent decrease in the inflammatory reactions that reduce the activation of leukocytes and monocytes [28], leading to less adhesion.

We recognized some limitations with this study. First, the use of healthy animals did not allow us to completely mimic the acute-on-chronic hypercapnic respiratory failure, where severe airflow limitation could not be simulated. Additionally, this limitation also prevents us to understand what could potentially challenge in clinical practice if there were to be device failure in non-ventilated patients. Furthermore, increasing acidosis (pH <7.25) over an extended period could not be replicated, due to a potential source of arrhythmia and, to an extent, stabilization of hypercapnic levels during the hypercapnic phase of the study. Nevertheless, the steady and gradual improvement in arterial pCO₂ and pH utilizing CO₂ dialysis in the given circumstance proved effective in ameliorating acute hypercapnia irrespective of the nature of anticoagulation. In the event of prolonged support, the influence of regional anticoagulation on CO₂ dialysis circuit life is worth investigating.

Conclusions

In conclusion, we demonstrated that low-flow CO₂ dialysis using a modified renal replacement system improved arterial pCO₂ significantly, thereby optimizing pH. Furthermore, regional anticoagulation with citrate would be an alternative option to circumvent bleeding complications. However, further studies are needed to determine if this approach is a viable option to potentially support patients with acute-on-chronic respiratory failure.

Competing interests

The authors declare that they have no competing interests.

Authors' contributions

AS contributed to the design, drafting, data analysis, and preparation of the manuscript. PW prepared and revised the manuscript. OB contributed to the sample analysis and revision of lab-related content. JGM contributed to the final approval. EFMW contributed to the revision and final approval. All authors read and approved the final manuscript.

Acknowledgements

We thank Ms Monique de Jong (Department of Cardiothoracic Surgery) for her expert biotechnical assistance.

Author details

¹Department of Cardiothoracic Surgery, CARIM, Maastricht University Medical Center, PO box 5800, 6202 AZ Maastricht, the Netherlands. ²Department of Clinical Chemistry, Maastricht University Medical Center, Maastricht, the Netherlands. ³Department of Respiratory Medicine, NUTRIM, Maastricht University Medical Center, Maastricht, the Netherlands.

Received: 23 June 2015 Accepted: 8 January 2016

Published online: 16 January 2016

References

1. Global Strategy for the Diagnosis MaPoC, Global Initiative for Chronic Obstructive Lung Disease (GOLD) (2014) Available from: <http://www.goldcopd.org/guidelines-global-strategy-for-diagnosis-management.html>
2. Hoo GW, Hakimian N, Santiago SM (2000) Hypercapnic respiratory failure in COPD patients: response to therapy. *Chest* 117(1):169–177
3. Terragni P, Maiolo G, Ranieri VM (2012) Role and potentials of low-flow CO₂ removal system in mechanical ventilation. *Curr Opin Crit Care* 18(1):93–98
4. Gattinoni L, Pesenti A, Kolobow T, Damia G (1983) A new look at therapy of the adult respiratory distress syndrome: motionless lungs. *Int Anesthesiol Clin* 21(2):97–117
5. Schmidt M, Tachon G, Devillers C, Muller G, Hekimian G, Brechot N, Merceron S, Luyt CE, Trouillet JL, Chastre J, Leprince P, Combes A (2013) Blood oxygenation and decarboxylation determinants during venovenous ECMO for respiratory failure in adults. *Intensive Care Med* 39(5):838–846
6. Berdajs DA, de Stefano E, Delay D, Ferrari E, Horisberger J, Ditmar Q, von Segesser LK (2011) The new advanced membrane gas exchanger. *Interact Cardiovasc Thorac Surg* 13(6):591–596
7. Khoshbin E, Westrope C, Pooboni S, Machin D, Killer H, Peek GJ, Sosnowski AW, Firmin RK (2005) Performance of polymethyl pentene oxygenators for neonatal extracorporeal membrane oxygenation: a comparison with silicone membrane oxygenators. *Perfusion* 20(3):129–134
8. Burki NK, Mani RK, Herth FJ, Schmidt W, Teschler H, Bonin F, Becker H, Randerath WJ, Stieglitz S, Hagemeyer L, Priegnitz C, Pfeifer M, Blaas SH, Putensen C, Theuerkauf N, Quintel M, Moerer O (2013) A novel extracorporeal CO₂ removal system: results of a pilot study of hypercapnic respiratory failure in patients with COPD. *Chest* 143(3):678–686
9. Batchinsky AI, Jordan BS, Regn D, Necsoiu C, Federspiel WJ, Morris MJ, Cancio LC (2011) Respiratory dialysis: reduction in dependence on mechanical ventilation by venovenous extracorporeal CO₂ removal. *Crit Care Med* 39(6):1382–1387
10. Iacovazzi M, Oreste N, Sardelli P, Barrettara B, Grasso S (2012) Extracorporeal carbon dioxide removal for additional pulmonary resection after pneumonectomy. *Minerva Anestesiol* 78(3):381–384
11. Livigni S, Maio M, Ferretti E, Longobardo A, Potenza R, Rivalta L, Selvaggi P, Vergano M, Bertolini G (2006) Efficacy and safety of a low-flow veno-venous carbon dioxide removal device: results of an experimental study in adult sheep. *Crit Care (London, England)* 10(5):R151. doi:10.1186/cc5082
12. Gray BW, Haft JW, Hirsch JC, Annich GM, Hirsch RB, Bartlett RH (2015) Extracorporeal life support: experience with 2,000 patients. *Am Soc Artif Internal Organ* 61(1):2–7
13. Extracorporeal Life Support Organization (2015) ELSO registry. Available at www.else.org/Registry/Statistics/InternationalSummary.aspx
14. Wu MY, Hsu YH, Bai CH, Lin YF, Wu CH, Tam KW (2012) Regional citrate versus heparin anticoagulation for continuous renal replacement therapy: a meta-analysis of randomized controlled trials. *Ame J Kidney Dis* 59(6):810–818
15. Bagshaw SM, Laupland KB, Boiteau PJ, Godinez-Luna T (2005) Is regional citrate superior to systemic heparin anticoagulation for continuous renal replacement therapy? A prospective observational study in an adult regional critical care system. *J Crit Care* 20(2):155–161
16. Morabito S, Pistolesi V, Tritapepe L, Vitaliano E, Zeppilli L, Polistena F, Fiaccadori E, Pierucci A (2013) Continuous venovenous hemodiafiltration with a low citrate dose regional anticoagulation protocol and a phosphate-containing solution: effects on acid-base status and phosphate supplementation needs. *BMC Nephrol* 14:232
17. Mariano F, Bergamo D, Gangemi EN, Hollo Z, Stella M, Triolo G (2011) Citrate anticoagulation for continuous renal replacement therapy in critically ill patients: success and limits. *Int J Nephrol* 2011:748320
18. Connors AF Jr, Dawson NV, Thomas C, Harrell FE Jr, Desbiens N, Fulkerson WJ, Kussin P, Bellamy P, Goldman L, Knaus WA (1996) Outcomes following acute exacerbation of severe chronic obstructive lung disease. The SUPPORT investigators (Study to Understand Prognoses and Preferences for Outcomes and Risks of Treatments). *Am J Respir Crit Care Med* 154(4 Pt 1):959–967
19. Hoogendoorn M, Hoogenveen RT, Rutten-van Molken MP, Vestbo J, Feenstra TL (2011) Case fatality of COPD exacerbations: a meta-analysis and statistical modelling approach. *Eur Respir J* 37(3):508–515
20. Ambrosino N, Vagheggini G (2008) Noninvasive positive pressure ventilation in the acute care setting: where are we? *Eur Respir J* 31(4):874–886
21. Menzies R, Gibbons W, Goldberg P (1989) Determinants of weaning and survival among patients with COPD who require mechanical ventilation for acute respiratory failure. *Chest* 95(2):398–405
22. Karagiannidis C, Kampe KA, Sipmann FS, Larsson A, Hedenstierna G, Windisch W, Mueller T (2014) Venovenous extracorporeal CO₂ removal for the treatment of severe respiratory acidosis: pathophysiological and technical considerations. *Crit Care (London, England)* 18(3):R124. doi:10.1186/cc13928
23. Banga A, Khilnani GC (2009) Post-hypercapnic alkalosis is associated with ventilator dependence and increased ICU stay. *COPD* 6(6):437–440
24. Forster C, Schriewer J, John S, Eckardt KU, Willam C (2013) Low-flow CO₂ removal integrated into a renal-replacement circuit can reduce acidosis and decrease vasopressor requirements. *Crit Care* 17(4):R154. doi:10.1186/cc12833

25. Conrad SA, Zwischenberger JB, Grier LR, Alpard SK, Bidani A (2001) Total extracorporeal arteriovenous carbon dioxide removal in acute respiratory failure: a phase I clinical study. *Intensive Care Med* 27(8):1340–1351
26. Tolwani A, Wille KM (2012) Advances in continuous renal replacement therapy: citrate anticoagulation update. *Blood Purif* 34(2):88–93
27. Cardenas VJ Jr, Miller L, Lynch JE, Anderson MJ, Zwischenberger JB (2006) Percutaneous venovenous CO₂ removal with regional anticoagulation in an ovine model. *Am Soc Artificial Internal Organ* 52(4):467–470
28. Bos JC, Grooteman MP, van Houte AJ, Schoorl M, van Limbeek J, Nube MJ (1997) Low polymorphonuclear cell degranulation during citrate anticoagulation: a comparison between citrate and heparin dialysis. *Nephrol Dial Transplant* 12(7):1387–1393

Submit your manuscript to a SpringerOpen[®] journal and benefit from:

- ▶ Convenient online submission
- ▶ Rigorous peer review
- ▶ Immediate publication on acceptance
- ▶ Open access: articles freely available online
- ▶ High visibility within the field
- ▶ Retaining the copyright to your article

Submit your next manuscript at ▶ springeropen.com
